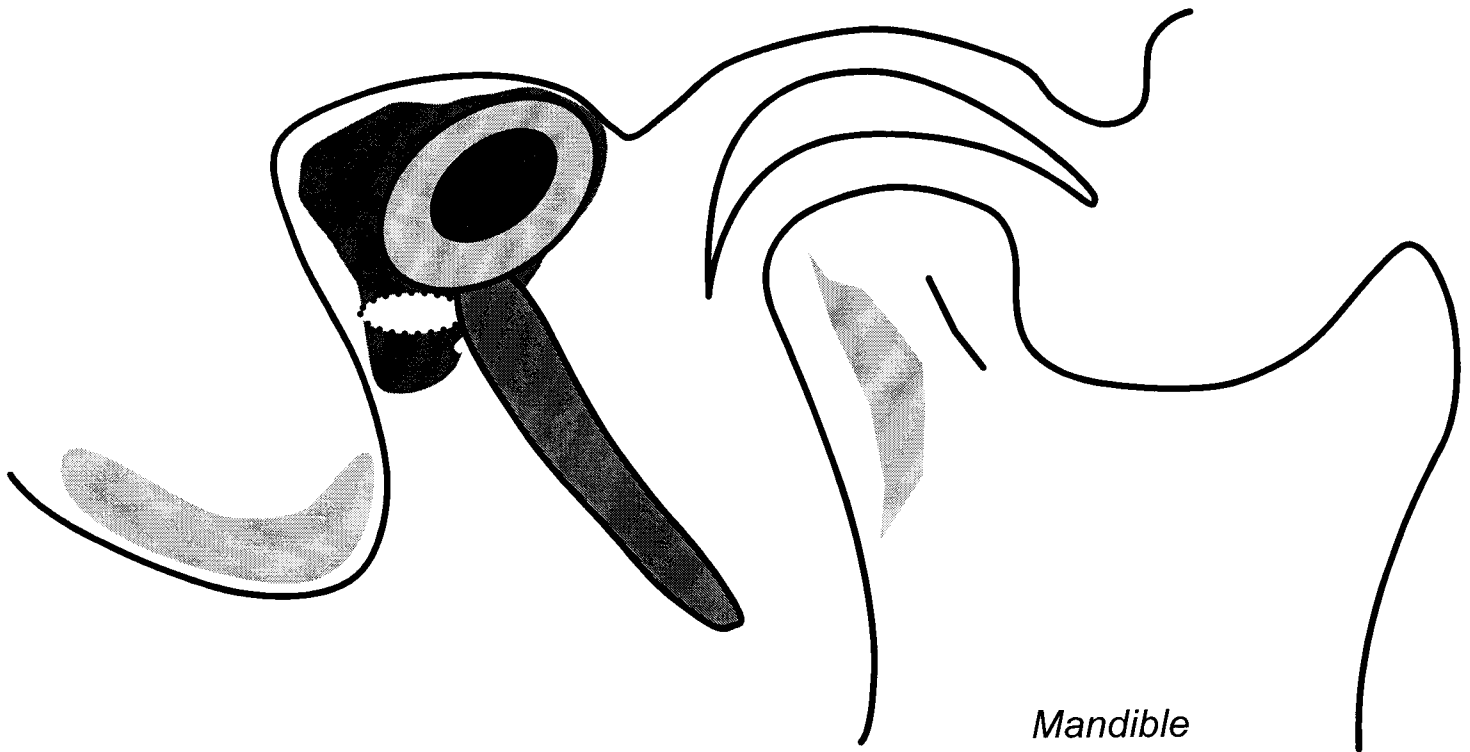
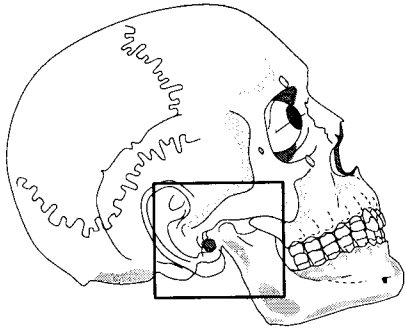


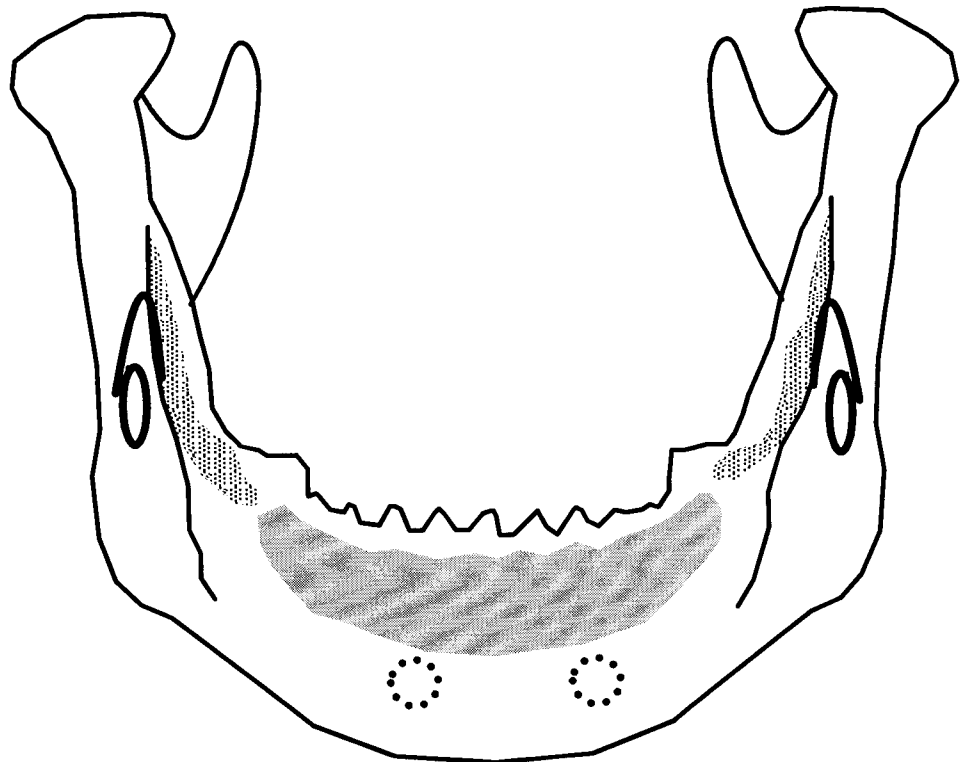
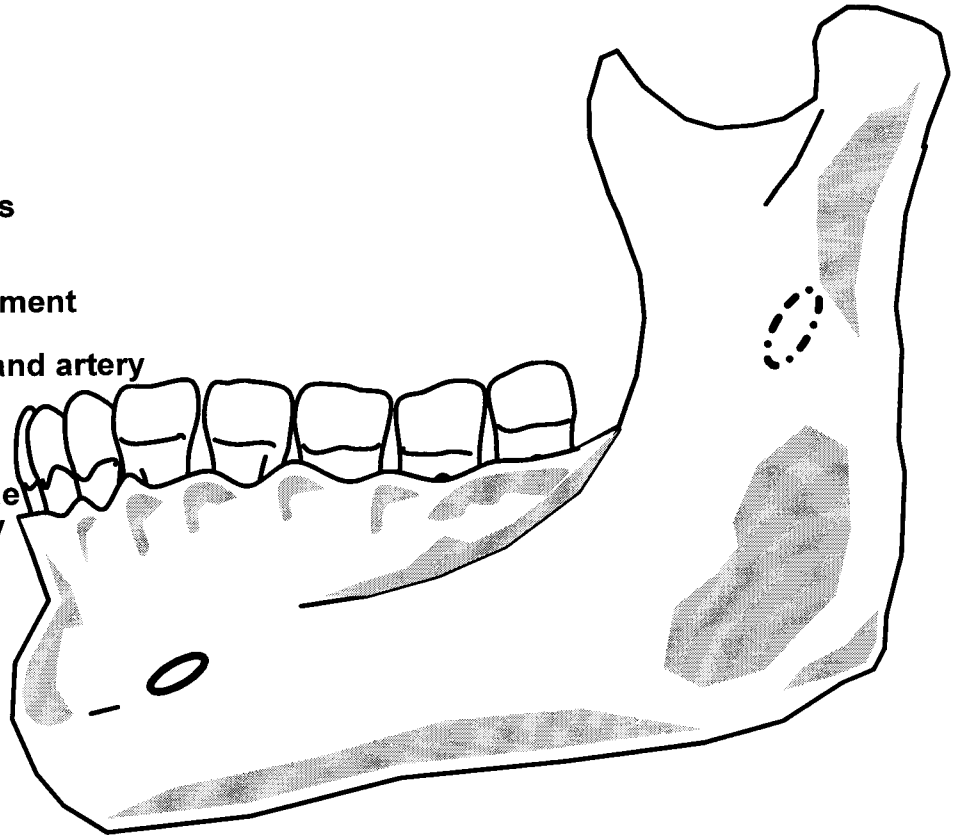
Temporomandibular Joint



1. Mastoid process
2. Styloid process
3. Stylomastoid foramen
4. External acoustic meatus
5. Postglenoid tubercle
6. Mandibular fossa
7. Articular tubercle
8. Condyle
9. Mandibular notch
10. Masseteric artery
11. Masseteric nerve
12. Coronoid process
13. Articular capsule
14. Superior synovial cavity
15. Articular Disk
16. Inferior synovial cavity
17. Superior head of lateral pterygoid
18. Inferior head of lateral pterygoid
19. Posterior fibers of temporalis
20. Anterior fibers of temporalis
21. Facial nerve
22. Auriculotemporal nerve
23. Communicating branch (parasympathetics)
24. Posterior belly digastric
25. Stylohyoid muscle
26. Lesser occipital nerve
27. Great auricular nerve
28. Parotid Gland

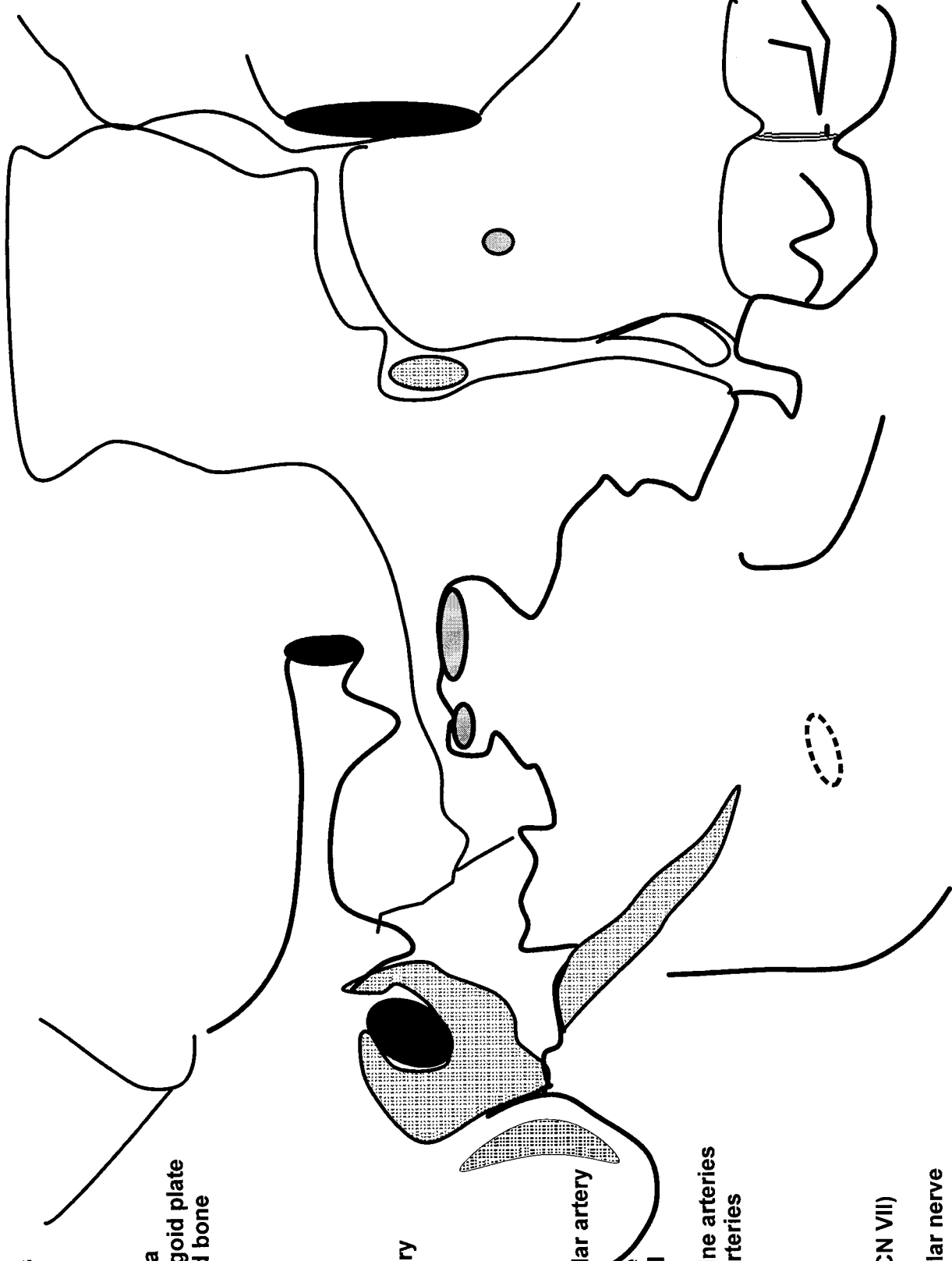
Lateral and Posterior View of Mandible

1. Condyle
2. Neck
3. Coronoid process
4. Mandibular notch
5. Ramus
6. Angle
7. Body
8. Inferior alveolar process
9. Mandibular foramen
10. Lingula
11. Sphenomandibular ligament
12. Mental foramen
13. Inferior alveolar nerve and artery
14. Inferior dental plexus
15. Temporalis muscle
16. Masseter muscle
17. Medial pterygoid muscle
18. Mental nerve and artery



Nerves of the Infratemporal Fossa

1. Zygomatic process temporal bone
2. Mastoid process
3. External auditory meatus
4. Styloid process
5. Petrotympanic fissure
6. Lateral pterygoid plate
7. Maxilla
8. Temporal process maxilla
9. Hamulus of medial pterygoid plate
10. Greater wing of sphenoid bone
11. Inferior orbital fissure
12. Pterygomaxillary fissure
13. Pterygopalatine fossa
14. Foramen spinosum
15. Foramen ovale
16. Sphenopalatine foramen
17. External carotid artery
18. Superficial temporal artery
19. Maxillary artery
20. Deep auricular artery
21. Inferior alveolar artery
22. Middle meningeal artery
23. Deep temporal arteries
24. Buccal artery
25. Posterior superior alveolar artery
26. Infraorbital artery
27. Artery of maxillary nerve
28. Artery of pterygoid canal
29. Pharyngeal artery
30. Greater and lesser palatine arteries
31. Lateral posterior nasal arteries
32. Mandibular nerve
33. Auriculotemporal nerve
34. Inferior alveolar nerve
35. Lingual nerve
36. Buccal nerve
37. Chorda tympani nerve (CN VII)
38. Maxillary nerve
39. Posterior superior alveolar nerve
40. Infraorbital nerve
41. Mandibular Foramen
42. Facial Nerve
43. Communicating branch - parasympathetics



Arteries of the Infratemporal Fossa

1. Zygomatic process temporal bone
2. Mastoid process
3. External auditory meatus
4. Styloid process
5. Petrotympanic fissure
6. Lateral pterygoid plate
7. Maxilla
8. Temporal process maxilla
9. Hamulus of medial pterygoid plate
10. Greater wing of sphenoid bone
11. Inferior orbital fissure
12. Pterygomaxillary fissure
13. Pterygopalatine fossa
14. Foramen spinosum
15. Foramen ovale
16. Sphenopalatine foramen
17. External carotid artery
18. Superficial temporal artery
19. Maxillary artery
20. Deep auricular artery
21. Inferior alveolar artery
22. Middle meningeal artery
23. Deep temporal arteries
24. Buccal artery
25. Posterior superior alveolar artery
26. Infraorbital artery
27. Artery of maxillary nerve
28. Artery of pterygoid canal
29. Pharyngeal artery
30. Greater and lesser palatine arteries
31. Lateral posterior nasal arteries
32. Mandibular nerve
33. Auriculotemporal nerve
34. Inferior alveolar nerve
35. Lingual nerve
36. Buccal nerve
37. Chorda tympani nerve (CN VII)
38. Maxillary nerve
39. Posterior superior alveolar nerve
40. Infraorbital nerve
41. Mandibular Foramen
42. Facial Nerve
43. Communicating branch - parasympathetics

