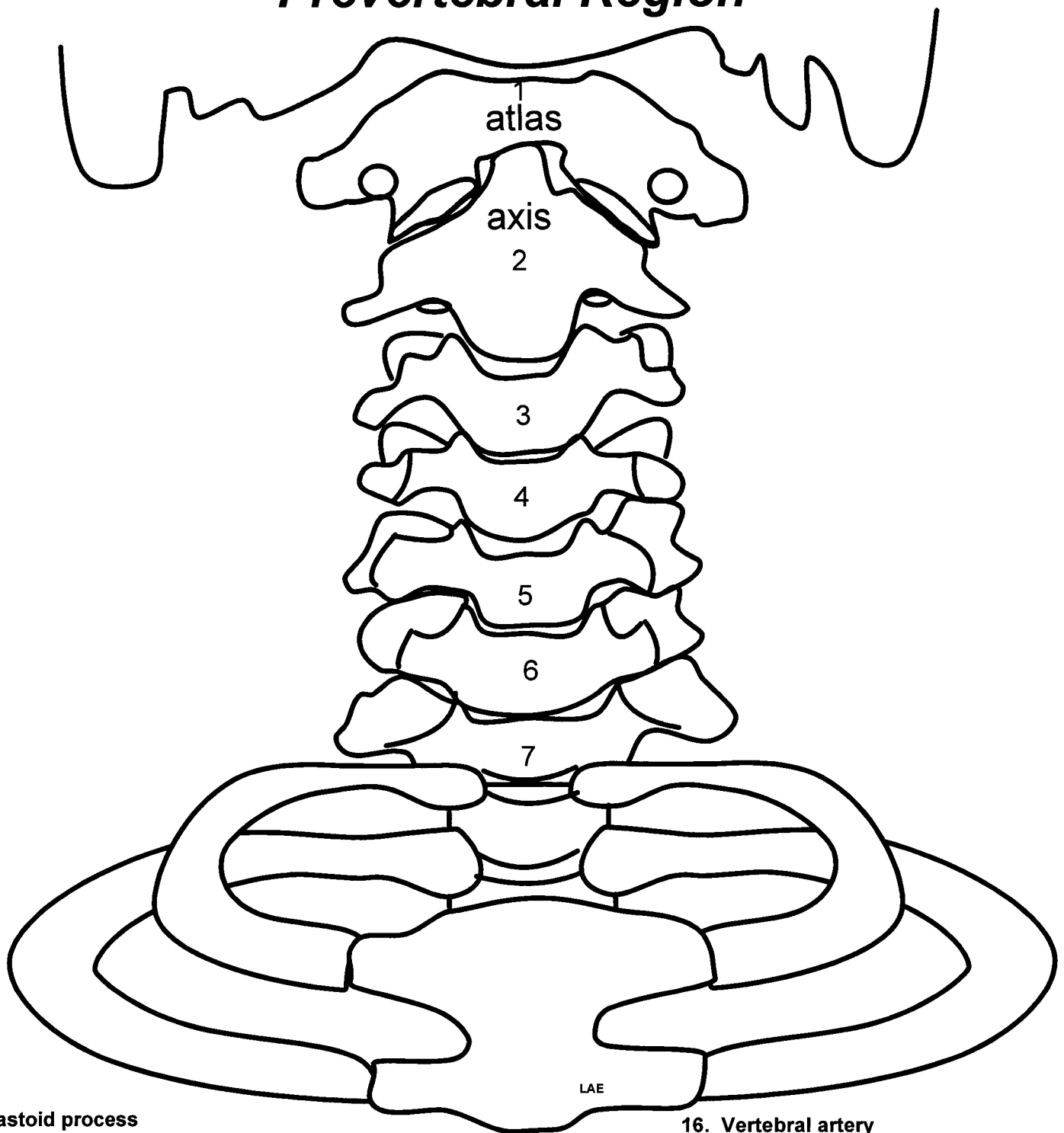


Prevertebral Region



1. Mastoid process
2. Groove for posterior belly digastric
3. Styloid process
4. Stylomastoid foramen
5. Facial nerve
6. Jugular foramen
7. Internal jugular vein
8. Glossopharyngeal nerve (CN IX)
9. Vagus nerve (CN X)
10. Spinal accessory nerve (CN XI)
11. Hypoglossal nerve (CNXII)
12. Longus colli muscle
13. Longus capitus muscle
14. Subclavian artery
15. Common carotid artery

16. Vertebral artery
17. Transverse foramen of atlas
18. Thyrocervical trunk
19. Inferior thyroid artery
20. Ascending cervical artery
21. Transverse cervical artery
22. Suprascapula artery
23. Thoracic sympathetic trunk
24. Stellate ganglion
25. Vertebral cervical sympathetic ganglion
26. Middle cervical sympathetic ganglion
27. Superior cervical sympathetic ganglion
28. Internal carotid artery
29. Internal carotid nerve and plexus
30. Ansa subclavia