

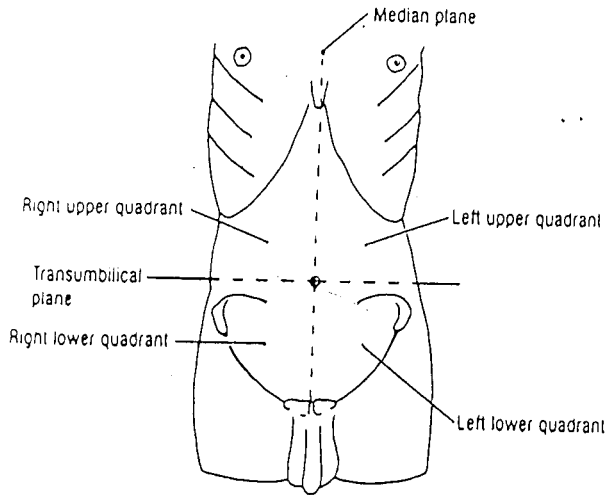Figure 4.02. The four abdominal quadrants.

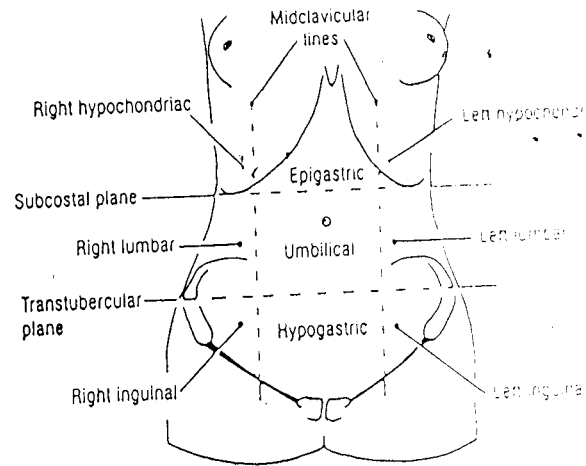


Figure 4.03. The nine abdominal regions

*From: Scott's Dissector*

Abdominal quadrants

Right upper quadrant (RUQ)
Liver: right lobe Gallbladder Stomach: pylorus Duodenum: parts 1-3 Pancreas: head Right suprarenal gland Right kidney Right colic (hepatic) flexure Ascending colon: superior part Transverse colon: right half

Left upper quadrant (LUQ)
Liver: left lobe Spleen Stomach Jejunum and proximal ileum Pancreas: body and tail Left kidney Left suprarenal gland Left colic (splenic) flexure Transverse colon: left half Descending colon: superior part

Right lower quadrant (RLQ)
Cecum Vermiform appendix Most of ileum Ascending colon: inferior part Right ovary Right uterine tube Right ureter: abdominal part Right spermatic cord: abdominal part Uterus (if enlarged) Urinary bladder (if very full)

Left lower quadrant (LLQ)
Sigmoid colon Descending colon: inferior part Left ovary Left uterine tube Left ureter: abdominal part Left spermatic cord: abdominal part Uterus (if enlarged) Urinary bladder (if very full)

*From: Moore + Dalley  
5th Edition*