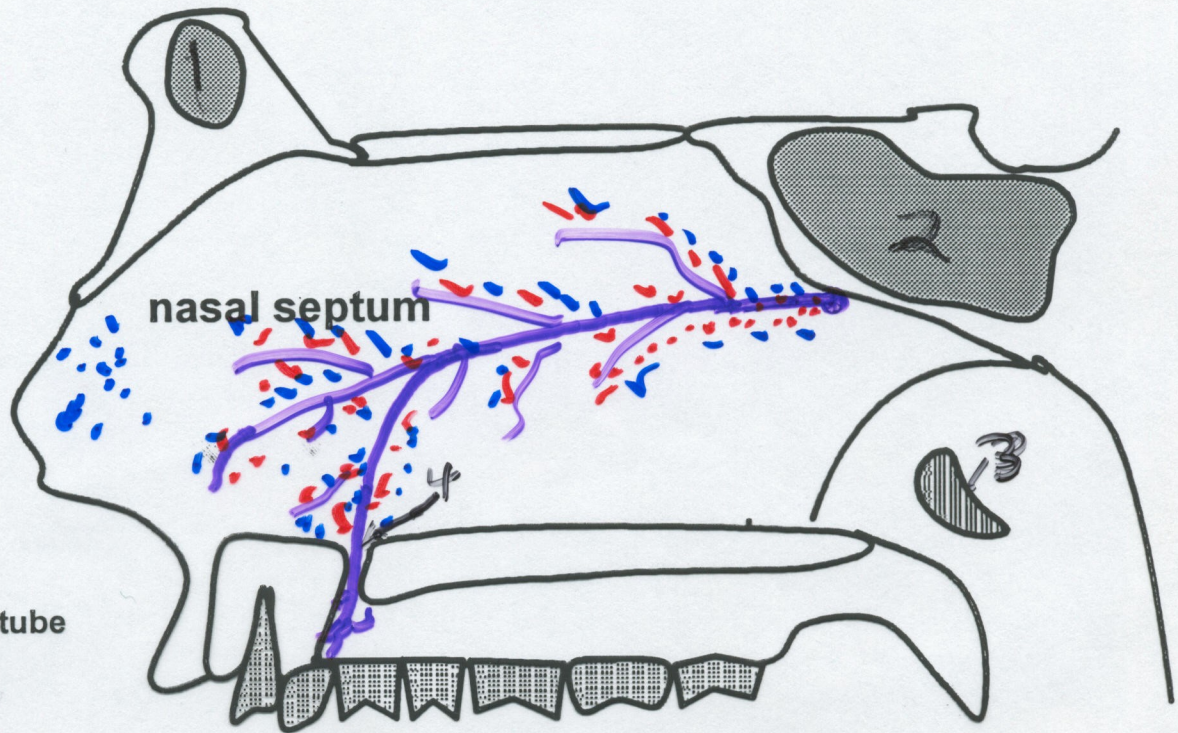
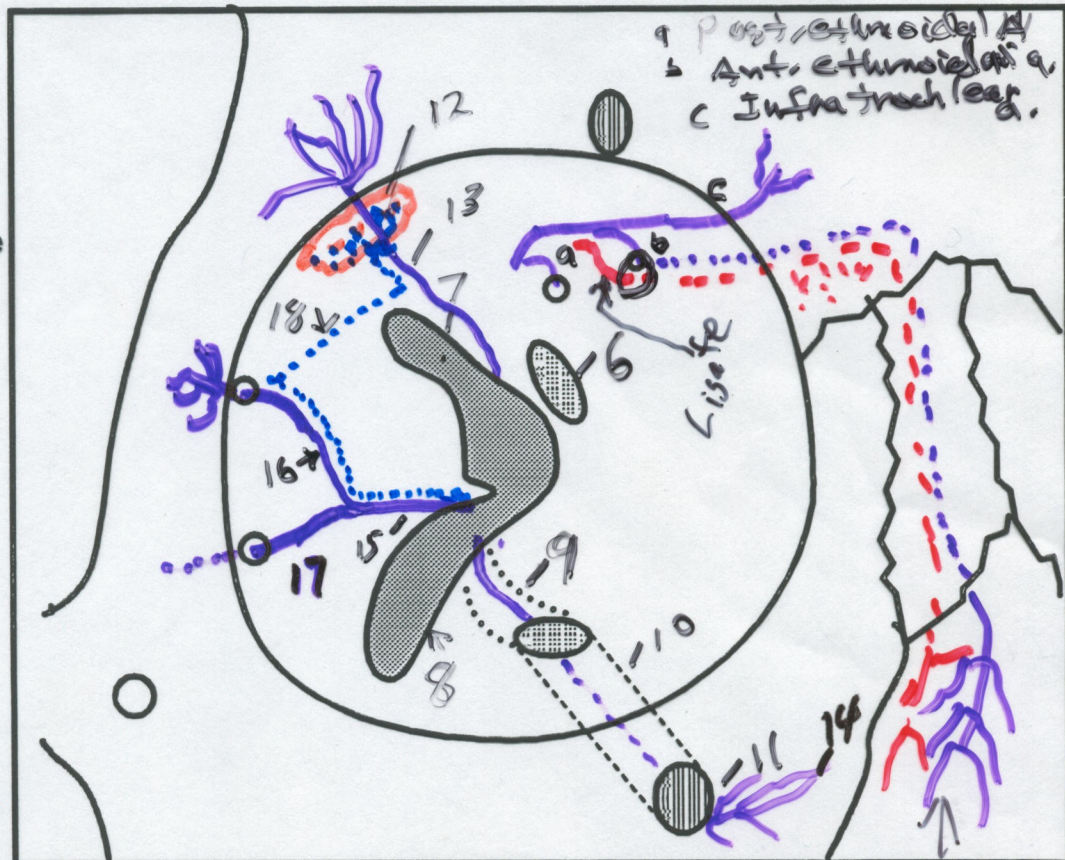


Trigeminal Nerve Branches Nasal Septum and Orbit

P0186



1. Frontal sinus
2. Sphenoid sinus
3. Ostium of auditory tube
4. Incisive canal
5. Nasopalatine nerve
6. Optic canal
7. Superior orbital fissure
8. Inferior orbital fissure
9. Infraorbital groove
10. Infraorbital canal
11. Infraorbital foramen
12. Lacrimal gland
13. Lacrimal nerve
14. Infraorbital nerve
15. Zygomatic nerve
16. Zygomaticotemporal nerve
17. Zygomaticofacial nerve
18. Communicating branch (parasympathetics)



MCF
 (gubernous)
 ↓
 sup. orbit. fissure
 ↓
 orbit
 ↓
 Ant. ethmoid. For.
 ↓
 Ethmoidal air cells
 ↓
 Ant. ethmoid. fossa
 ↓
 nasal cavity

↳ External nasal N. → Face

Ext. Nasal