Perineum
Illustration: Natalie Yoshioka

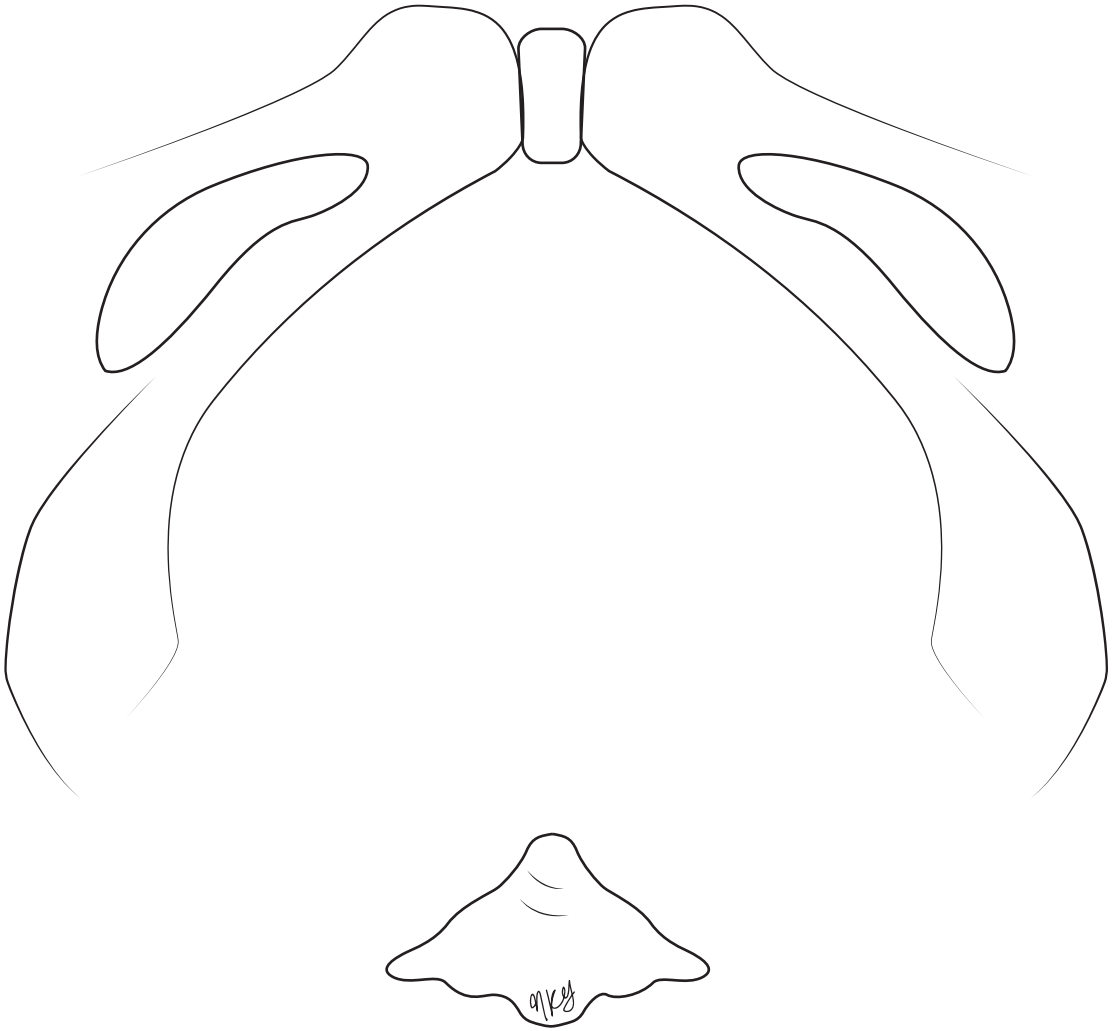

Posterior Recess of Ischioanal Fossa
Illustration: Natalie Yoshioka

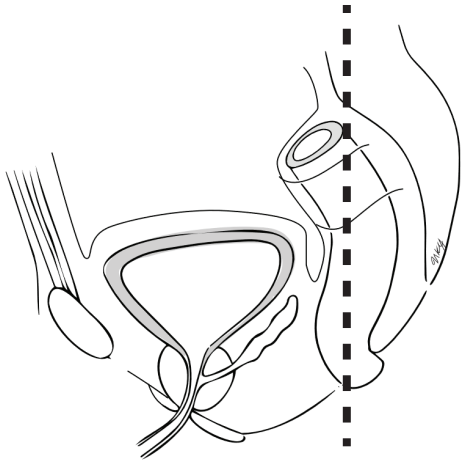

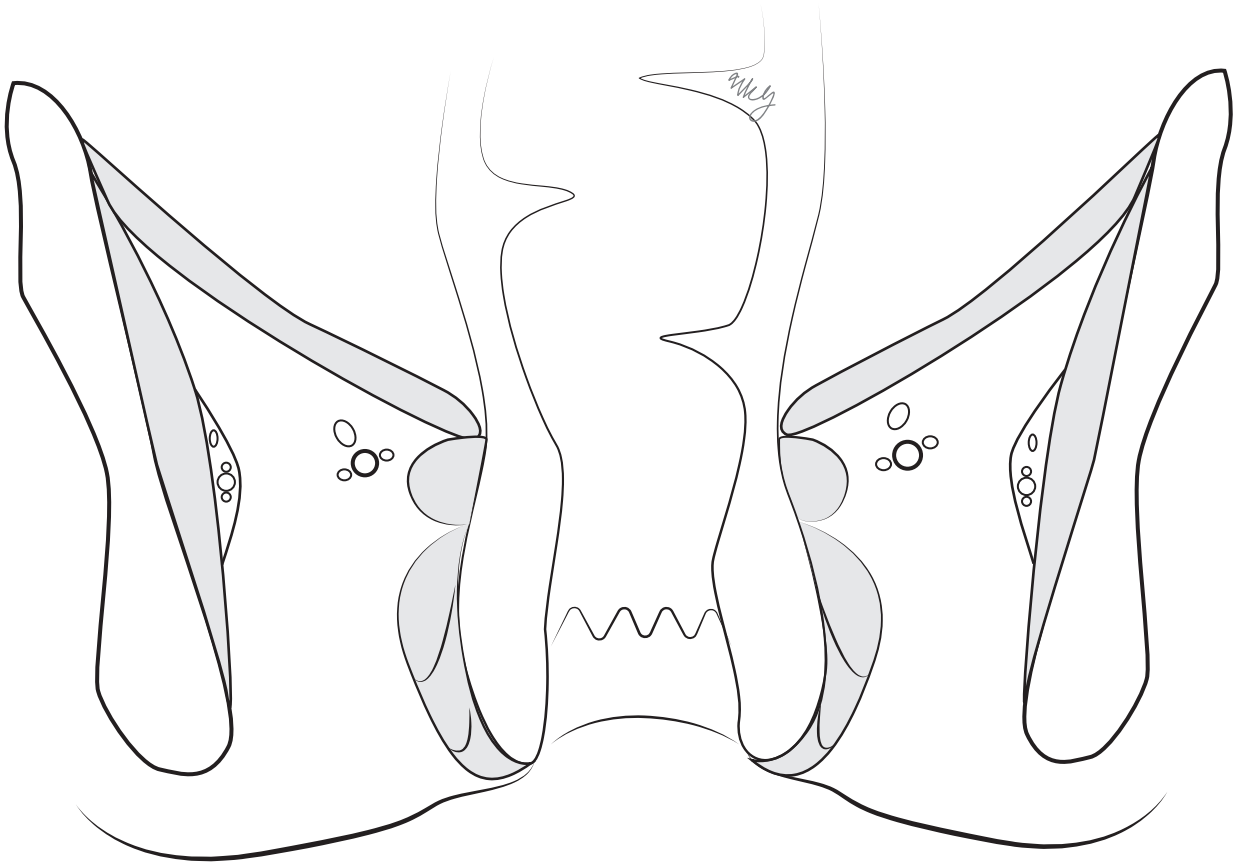

Anterior Recess of Ischioanal Fossa
Illustration: Natalie Yoshioka

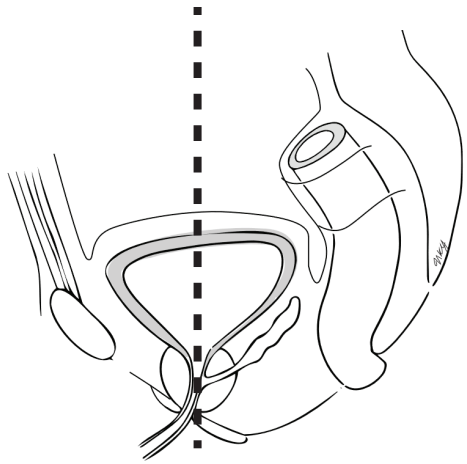

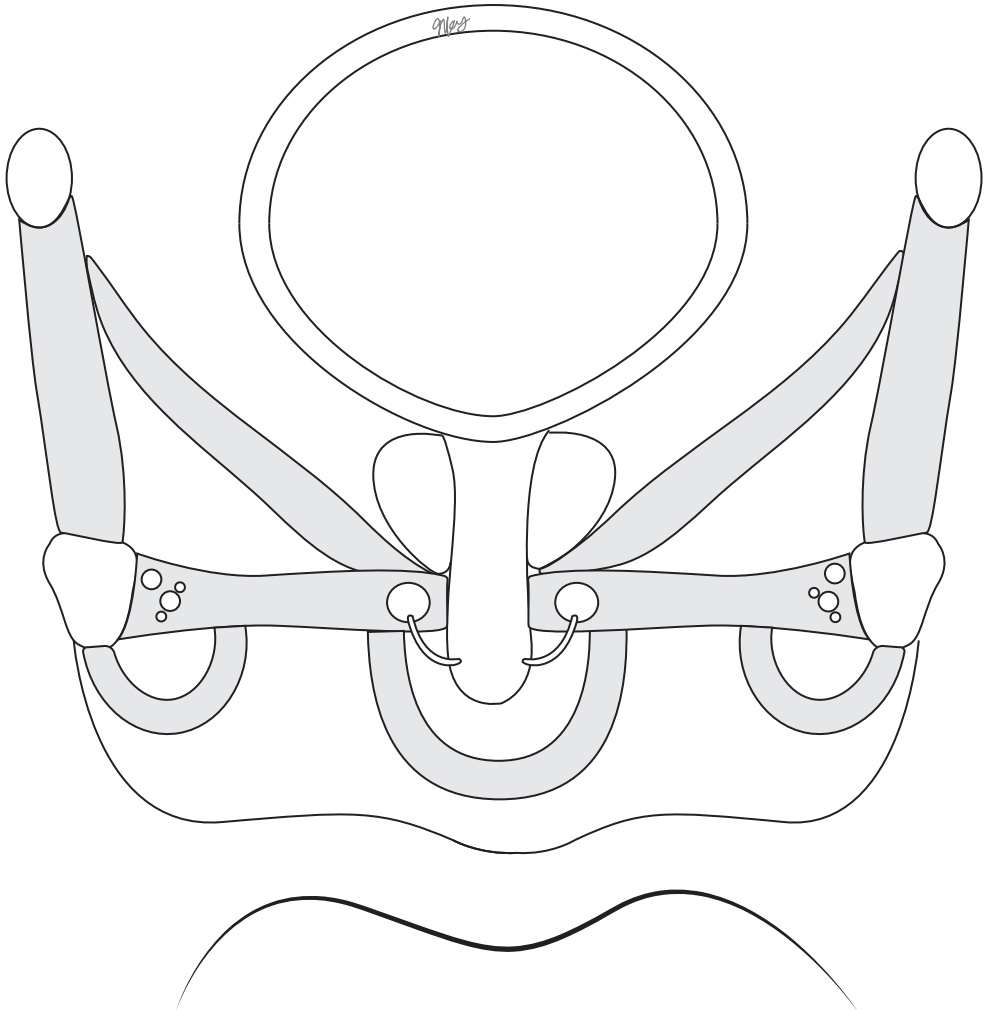
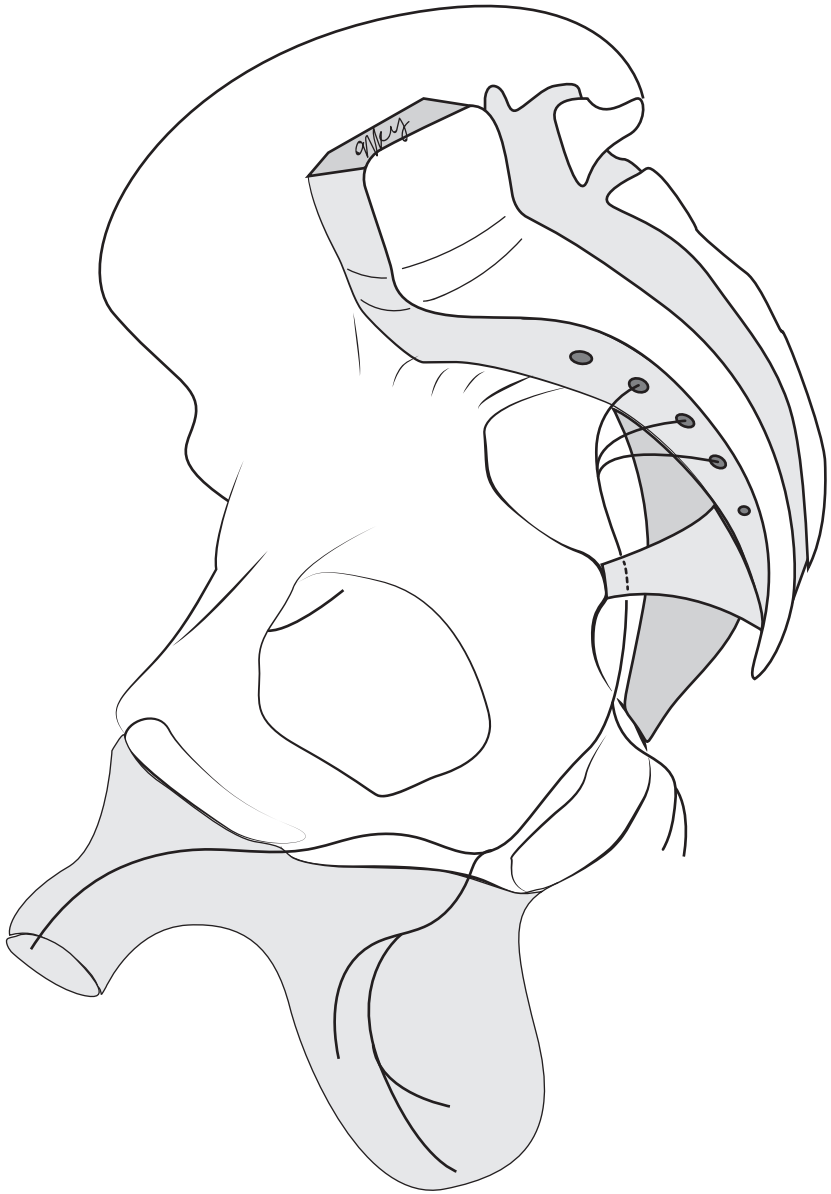
Pudendal Nerve
Illustration: Natalie Yoshioka