Female Internal Iliac Artery
Illustration: Natalie Yoshioka

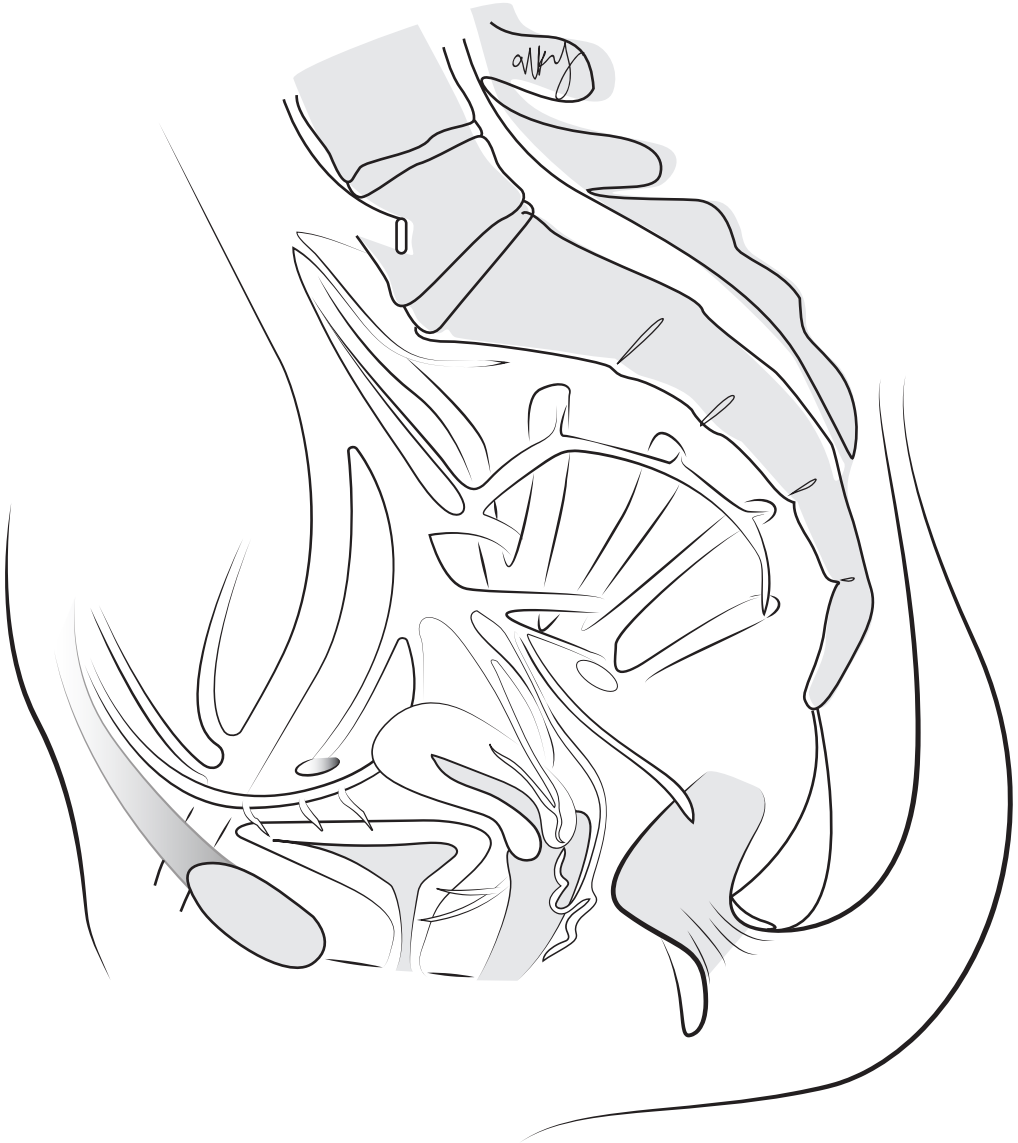

Male Internal Iliac Artery
Illustration: Natalie Yoshioka

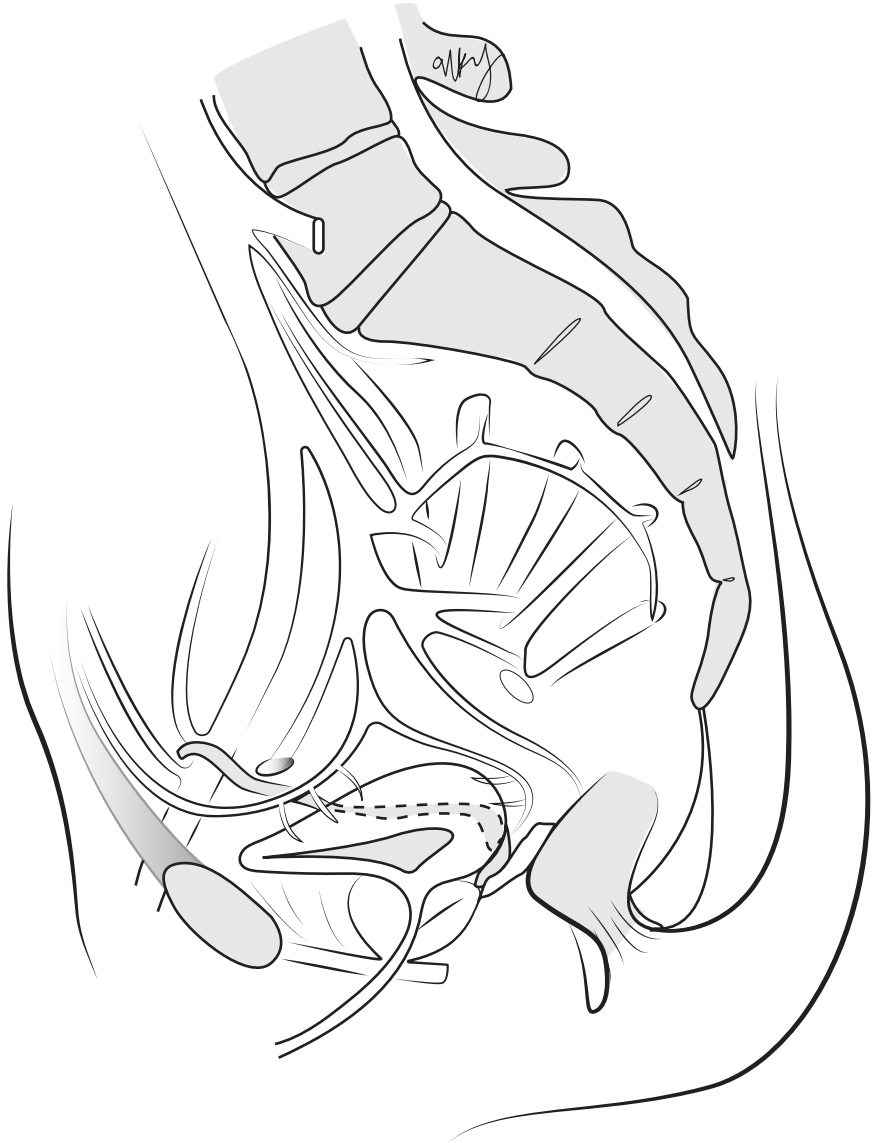

Autonomics of the pelvis
Illustration: Natalie Yoshioka

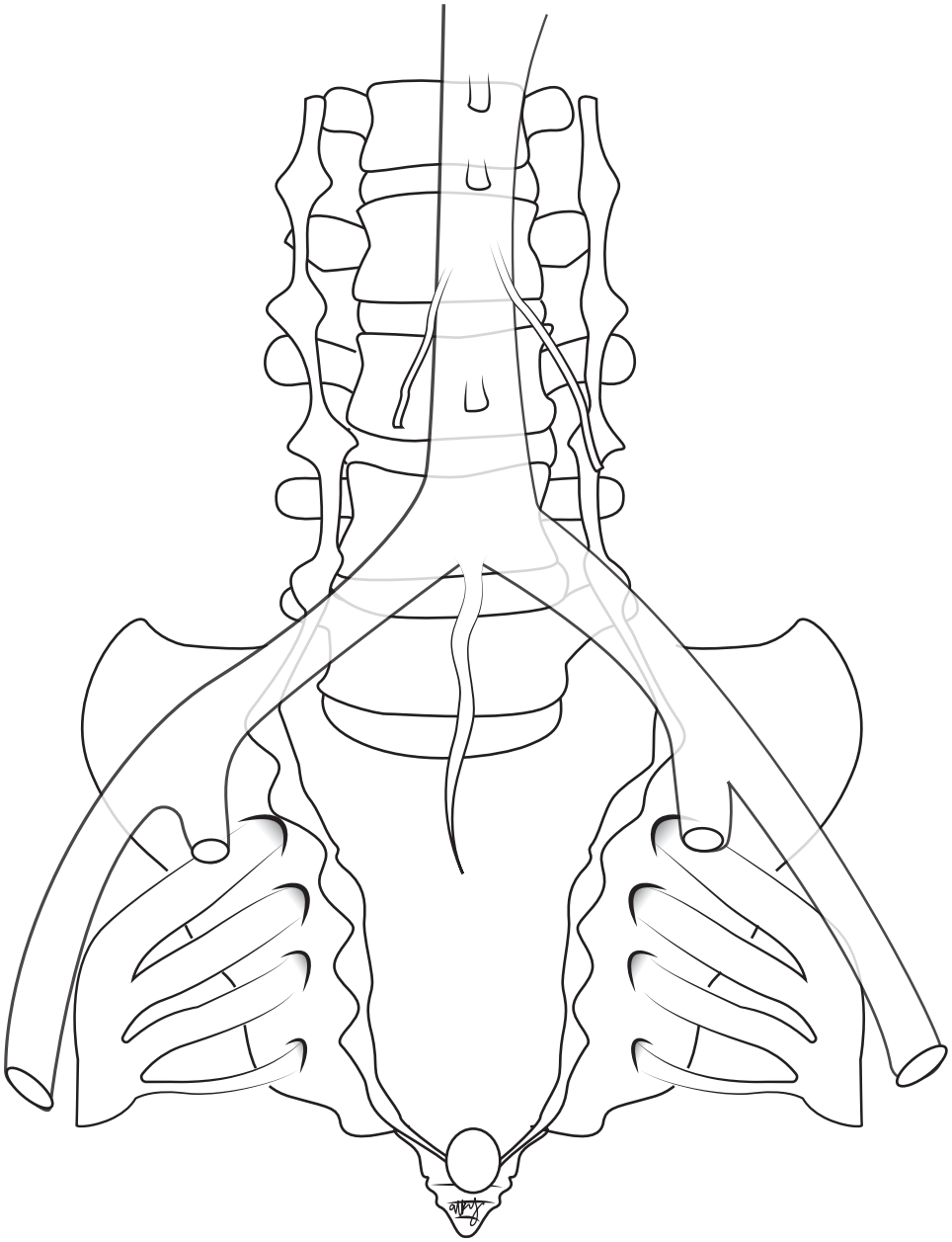
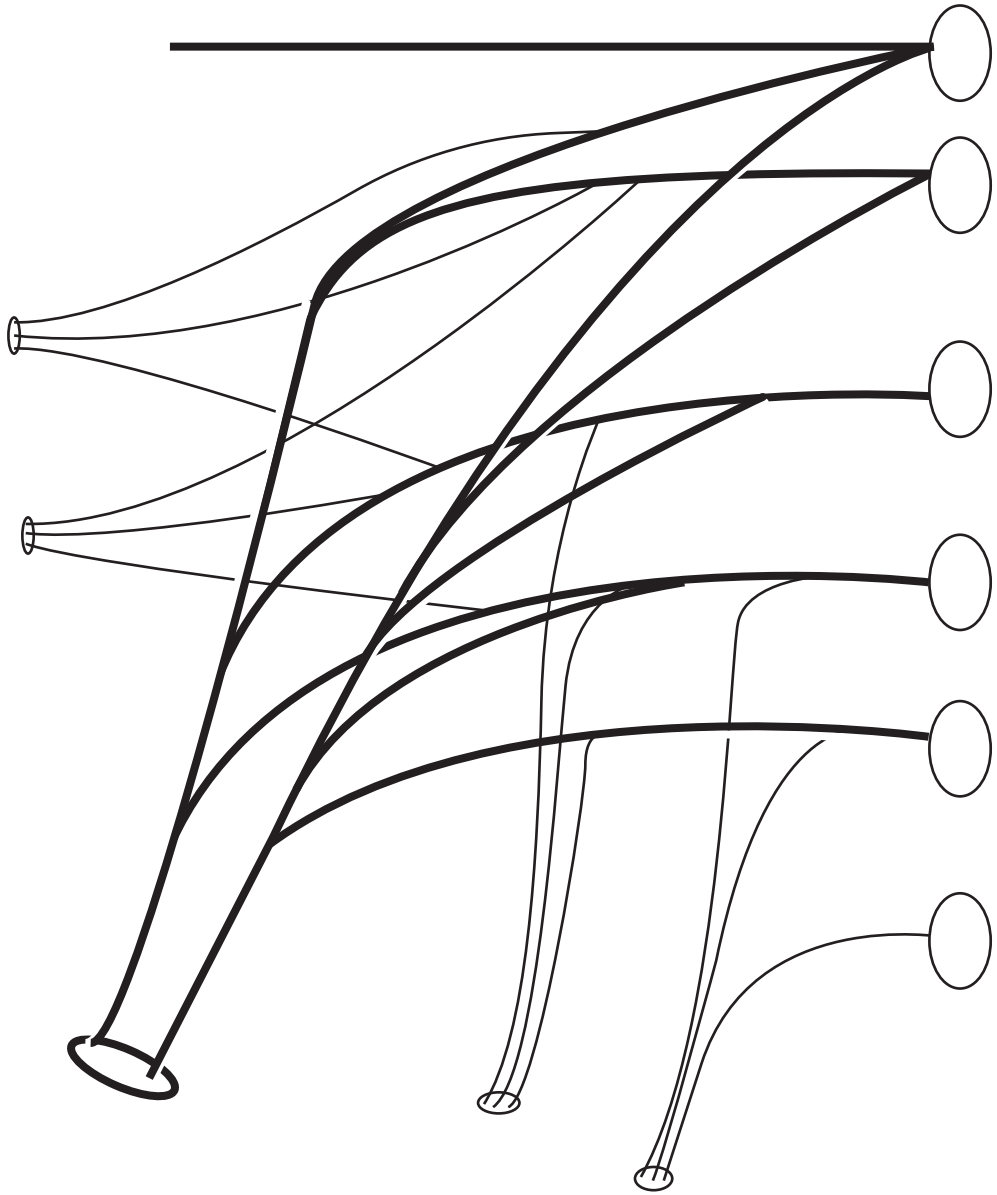
Sacral Plexus
Illustration: Natalie Yoshioka